

# Dizziness in orthopaedic physical therapy practice: vestibular system anatomy, vascularization, and physiology with clinical implications

## Zawroty głowy w praktyce fizjoterapii ortopedycznej: anatomia układu przedsionkowego, jego unaczynienie i fizjologia oraz ich implikacje kliniczne

Peter Huijbregts PT MSc MHSc DPT OCS MTC FAAOMPT FCAMT

Paul Vidal PT MHSc DPT OCS MTC

### Key words

dizziness, vertigo, vestibular, anatomy, vascularization, physiology

### Summary

Dizziness is a frequent complaint in orthopaedic physical therapy and general medical practice. It can result from dysfunctions in multiple body systems relevant to balance control. Knowledge of vestibular anatomy, vascular supply, and vestibular and visual system physiology is a necessary prerequisite for the successful clinical diagnosis and management of patients complaining of dizziness. This article discusses peripheral and central vestibular anatomy and relevant afferent and efferent pathways with emphasis on the vestibulo-ocular, vestibulo-spinal, and vestibulo-colic reflex circuits. The article also provides information on vestibular system vascularization and vestibular and relevant visual system physiology including a discussion of the contribution to gaze stabilization by the vestibulo-ocular and cervico-ocular reflex circuits, the smooth pursuit and saccadic systems, and the optokinetic response. The basic science information provided is made clinically relevant by discussing specific clinical implications for evaluation and management of patients with a main complaint of dizziness clarifying the need for comprehensive multi-system evaluation in this patient group.

### Słowa kluczowe

zawroty głowy, vertigo, układ przedsionkowy, unaczynienie, fizjologia

### Streszczenie

Zawroty głowy są dolegliwością często zgłaszaną przez pacjentów w fizjoterapii ortopedycznej i ogólnej praktyce medycznej. Mogą być wynikiem dysfunkcji wielu układów istotnych dla utrzymywania równowagi. Znajomość anatomii układu przedsionkowego, jego ukrwienia oraz fizjologii układu przedsionkowo-wzrokowego jest koniecznym warunkiem skutecznego klinicznego diagnozowania i postępowania z pacjentami skarżącymi się na zawroty głowy. W artykule omawiana jest obwodowa i ośrodkowa anatomia układu przedsionkowego z odpowiadającymi eferentnymi i aferentnymi drogami nerwowymi, ze szczególnym uwzględnieniem odruchowych pętli przedsionkowo-ocznych, przedsionkowo-rdzeniowych i przedsionkowo-szyjnych. Artykuł zawiera także informacje dotyczące unaczynienia układu przedsionkowego oraz fizjologii układu przedsionkowego i odpowiadających zagadnień dotyczących układu wzrokowego. Omówiony jest udział odruchów przedsionkowo-ocznych i szyjno-ocznych, systemu płynnego śledzenia i sakkadowego oraz odpowiedzi optokinetycznej w stabilizacji funkcji widzenia. Informacje dotyczące nauk podstawowych są odniesione do sytuacji klinicznych poprzez przedstawienie ich znaczenia dla badania pacjenta, którego główną dolegliwością są zawroty głowy. Wskazana jest konieczność całościowego wieloukładowego badania pacjentów tej grupy.

### Introduction

Dizziness is a frequent patient complaint in orthopaedic physical therapy and general medical practice. It can result from dysfunctions in multiple body systems relevant to balance control. Proper balance control requires multi-system integration: visual, vestibular, auditory, tactile, propriocep-

tive, and cognitive input is integrated to produce an appropriate motor output. Extensive connections exist between the vestibular nuclear complex, the cerebellum, the ocular motor nuclei, the brainstem reticular activating system, and higher cortical centers to formulate appropriate signals for the effector organs of the balance system,

i.e., the extra-ocular and skeletal muscles<sup>1</sup>. In-depth understanding of the anatomy, vascularization, and physiology of especially the vestibular system is a prerequisite to the successful differential diagnosis of patients complaining of dizziness.

The goal of this article is to provide said prerequisite knowledge by way of

a review of anatomy of the vestibular system and its afferent and efferent pathways, vascularization of the vestibular system, and vestibular and relevant visual system physiology. The article will also relate this information to the clinical diagnosis and management of patients complaining of dizziness. A comprehensive discussion of anatomy and physiology of the visual, auditory, cognitive, and somatosensory systems is outside the scope of this review and we refer the reader to relevant anatomy texts for a discussion of these topics.

## Anatomy

As noted above, balance control depends on the integrity of multiple anatomical systems. We will discuss vestibular anatomy with its peripheral and central components and relevant afferent and efferent pathways. The peripheral component of the human vestibular system (Figure 1) consists of bilateral:

1. Bony labyrinths
2. Membranous labyrinths
3. Vestibular motion sensors

The bony labyrinth is part of the inner ear and is located in the petrous portion of the temporal bone<sup>1,2</sup>. It consists of three semicircular canals, oriented perpendicularly to one another, and a central chamber called the vestibule. The bony labyrinth is filled with perilymphatic fluid. This fluid communicates with the cerebrospinal fluid in the subarachnoid space by way of the cochlear aquaduct. As is the case with cerebrospinal fluid, perilymphatic fluid has a high sodium-to-potassium (Na: K) ratio<sup>1</sup>. The membranous labyrinth is located within this bony labyrinth. It is held in place by the perilymphatic fluid and by supportive connective tissue structures<sup>1</sup>. The membranous labyrinth consists of five sensory organs, the membranous portions of the three semicircular canals and two otolith organs, the utricle and the saccule<sup>1</sup>. The membranous labyrinth is filled with endolymphatic fluid<sup>1</sup>. In contrast to the perilymphatic fluid, this endolymphatic fluid has a high K: Na-ratio. Normally, the endolymphatic and perilymphatic compartments do not communicate<sup>1</sup>.

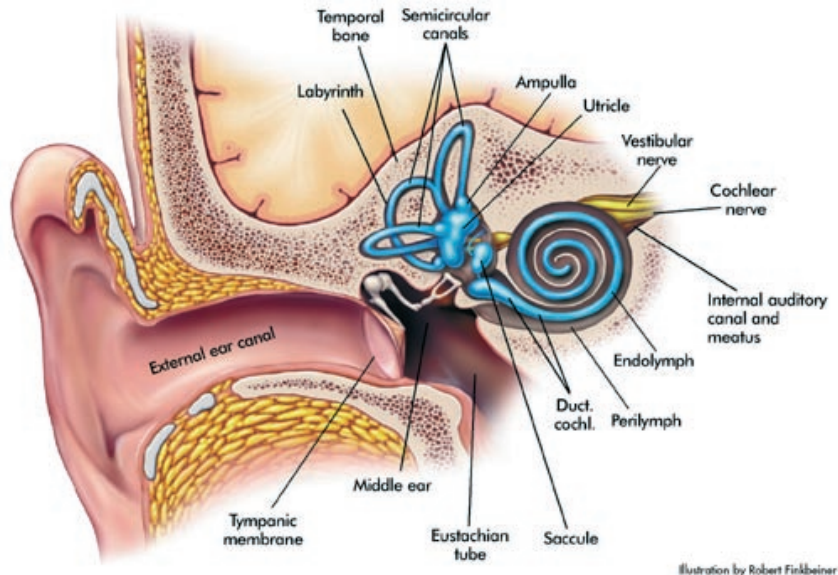


Illustration by Robert Finkbeiner

**Figure 1**

**Anatomy of the peripheral vestibular system** (Reproduced with permission from Herdman S.J., ed. *Vestibular Rehabilitation*. Philadelphia, PA: FA Davis Company, 1994; 4).

So in total, there are six semicircular canals: bilateral anterior, horizontal (or lateral), and posterior<sup>1</sup>. A semicircular canal widens in diameter at one end into the ampulla. Here, on a tuft of blood vessels, nerve fibers, and supportive tissue, called the crista ampullaris, the semicircular canal hair cells are located. These hair cells are the sensors that convert displacement due to head motion into neuronal activity<sup>1</sup>. The cupula is a gelatinous membrane overlying the crista ampullaris: it allows for coupling of the endolymphatic movement due to head motion to movement of the hair cells<sup>1,3</sup>. The semicircular canals are located in the same planes as the extra-ocular muscles; information from the semicircular canal hair cells provides the sensory input to the vestibulo-ocular reflex (VOR) for which the extra-ocular muscles are the effector organs<sup>1,3</sup>. The semicircular canal hair cells also provide afferent information for the vestibulo-colic (or vestibulo-cervical) reflex (VCR): the neck and proximal trunk muscles serve as effector organs for this reflex<sup>4</sup>.

The two otolith organs, utricle and saccule, are housed in the vestibule<sup>1,3</sup>. The hair cells of the otolith organs are called maculae; they are located on the medial wall of the saccule and on the floor of the utricle<sup>1</sup>. Membranes

similar to the cupula overlie the otolithic maculae. These otolithic membranes contain calcium carbonate crystals called otoconia. These crystals increase the mass of the otolithic membrane thus making the maculae sensitive to gravity. In contrast, the cupulae are not gravity-sensitive: they lack the otoconia and thus have the same density as the surrounding endolymphatic fluid<sup>1</sup>. The otolithic hair cells produce neuronal activity even at rest due to this gravity-sensitivity. Sensory information from the otolith organs serves as afferent input to the vestibulo-spinal reflex (VSR)<sup>1</sup>. Otolithic maculae also provide afferent information for the VCR: Watson and Colebatch<sup>5</sup> hypothesized a connection between the otolithic maculae, including the saccular maculae, and the sternocleidomastoid muscle.

The vestibular nerve consists of the afferent projections from bipolar neurons whose cell bodies are located in Scarpa's (vestibular) ganglion<sup>1</sup>. It courses through the internal auditory canal together with the cochlear nerve, the facial nerve and the labyrinthine artery<sup>1</sup>. The cochlear and vestibular nerve make up the vestibulocochlear nerve. Peripheral vestibular input is transmitted to the central processing unit of the vestibular system, which consists of the vestibulo-

lar nuclear complex and the cerebellum<sup>1,6</sup>. Sensory information received from the peripheral vestibular system is integrated in both centers with afferent information from the visual and somatosensory systems<sup>1</sup>. The vestibular nuclear complex is located in the pons and extends into the medulla<sup>1</sup>. The cerebellar flocculus plays a role in adjusting the gain of the VOR. The cerebellar nodulus processes otolith input. The anterior-superior cerebellar vermis plays a role in VSR and VCR regulation<sup>1</sup>.

Two tracts carry information from the vestibular nuclear complex to the nuclei responsible for extra-ocular muscle control<sup>1</sup>. The ascending tract of Deiters connects the vestibular complex to the ipsilateral abducens nucleus, which controls the lateral rectus muscle during the horizontal VOR. All other VOR-related output to the ocular motor nuclei is carried by the medial longitudinal fascicle.

Three pathways connect the vestibular nuclear complex to the effector organs for the VSR, the anterior motor neurons and their associated skeletal muscles<sup>1,5</sup>:

- The lateral vestibulospinal tract originates in the ipsilateral vestibular nuclei and controls anti-gravity postural muscle activity mainly in the legs.
- The medial vestibulospinal tract originates in part of the contralateral vestibular nuclei and descends only through the cervical spinal cord in the medial longitudinal fascicle innervating the cervical axial muscles.
- The reticulospinal tract receives input from all vestibular nuclei and sensory and motor systems relevant to balance. It courses partly crossing the midline and partly remaining ipsilateral throughout the spinal cord and plays a role in most balance reactions.

Because the neck receives vestibular projections that are more potent than those to the limbs, the cervical VSR has been identified as a separate reflex, the VCR<sup>5</sup>. The role of the VCR is to stabilize the position of the head in space<sup>4,5</sup>. The sternocleidomastoid muscle is the most accessible muscle to clinically study this reflex<sup>5</sup>, but the

VCR in fact controls all muscles that produce head-on-neck and neck-on-trunk rotation<sup>4</sup>. Contraction of these muscles counteracts angular rotation of the head and body by reflexively producing opposing head and neck rotation<sup>4</sup>. The connection between, e.g., the sternocleidomastoid muscles and the otolithic maculae<sup>5</sup> also indicates a possible role for the VCR in maintaining a stable head position during linear head and body movement. Most of the vestibulo-colic pathways are ipsilateral connections between vestibular hair cells and neck muscles located in the medial vestibulospinal tract but there is evidence of contralateral or crossed connections with small muscular reflex responses in the contralateral sternocleidomastoid muscle with unilateral vestibular system stimulation<sup>5</sup>.

### Clinical implications based on anatomy

Many different disease processes may affect the peripheral vestibular system and the history needs to be tailored to detecting symptoms indicative of these distinct pathologies<sup>7,8</sup>. The location of the peripheral vestibular system also makes it vulnerable to direct and indirect trauma.

Grimm<sup>9</sup> described either a damaged peripheral labyrinth or cochlea in 90% and both in 69% of a cohort of 227 post-whiplash patients presenting for a neurology evaluation. Of these patients, 92% met the diagnostic criteria for inner ear contusion. Of this subgroup, 63% was diagnosed with benign paroxysmal positional vertigo (BPPV), 64% with secondary endolymphatic hydrops, and 21% with unilateral or bilateral perilymphatic fistulae<sup>9</sup>.

A petrosal bone fracture due to direct trauma may damage the vestibulo-cochlear nerve with resultant vertigo and concomitant hearing loss<sup>7</sup>. Head injury but also barotrauma as a result of flying, diving, or a forceful Valsalva maneuver may result in a rupture in the oval or round window allowing for leakage of perilymphatic fluid from the inner ear into the middle ear. This may cause vertigo with hearing loss<sup>7</sup>. History tak-

ing in patients complaining of dizziness should, therefore, include questions regarding direct trauma, indirect trauma, and barotrauma.

A space-occupying process in the internal auditory canal can affect the vestibular afferent connections. Compression of the vestibulocochlear nerve and the closely associated facial nerve and labyrinthine artery result in hearing loss, vertigo, tinnitus, a sensation of fullness in the ear, and facial weakness<sup>7</sup>. Examination of the patient complaining of dizziness should include questions and tests for vestibulocochlear and facial nerve function<sup>7</sup>.

The central processing unit of the vestibular system consists of the vestibular nuclear complex and the cerebellum. The cranial nerve nuclei are closely associated with the central vestibular system. History and examination for the patient with dizziness needs to include questions and tests for cerebellar and cranial nerve dysfunction<sup>8</sup>.

Vestibular efferent pathways for the VOR consist of the medial longitudinal fascicle and the ascending tract of Deiters. The extra-ocular muscles are the effector organs. Examination of patients complaining of dizziness should include eye observation and tests for oculomotor function as included in the cranial nerve examination<sup>8</sup>.

Efferent pathways for the VSR and VCR are located in the brain stem, spinal cord, nerve roots, and the peripheral nerves. History and examination should include neuroconductive tests (strength, reflexes, and sensation), neurodynamic tests, and tests that evaluate for compromise of the neurological by the musculoskeletal system<sup>8</sup> (e.g., foraminal compression tests, spinal shear stability tests, and pathological reflexes, such as Hoffman and Babinski signs and ankle clonus).

The VSR effector organs are the skeletal muscles. The examination should include tests for muscle length, strength, coordination, and endurance<sup>8</sup>. Weakness in the hip, knee, and ankle region may not allow for an appropriate contractile response and has been shown to negatively affect balance<sup>10,11</sup>. Postural abnormalities may

adversely influence the location of the center of gravity in relation to the base of support. These postural deviations may be the result of myofascial and/or articular restrictions. An increased resistance throughout the range of motion has been found in older adults<sup>11</sup>. This will increase the demands on possibly already weakened contractile structures. The examination may include osteokinematic and arthrokinematic motion tests to determine the cause for possible decreased trunk extension, hip extension, knee extension, and ankle dorsiflexion<sup>8</sup>. Alexander<sup>11</sup> hypothesized that the relation between balance and muscle strength is not linear, but rather that there exists a threshold value for strength, below which balance is impaired, especially with multi-system involvement in older adults. Within this theoretical framework, the value of strength training to improve balance in this patient population becomes clear. The value of evaluation of joint function and -if indicated- of mobilization to decrease through-range resistance and increase end-range joint mobility should be clear. The role of posture in maintaining an optimum location of the center of gravity and possible therapeutic intervention to restore appropriate posture is equally obvious.

The neck and upper thoracic muscles responsible for head-on-neck and neck-on-trunk rotation are the effector organs for the VCR<sup>4</sup>. Decreased length, strength, coordination, and endurance of these muscles may result in inappropriate VCR output. An inability to optimally stabilize the head in space could in turn lead to aberrant afferent input to the vestibular nucleus complex and cerebellum. This aberrant afferent input could result from the eyes in the sense of an unexpected retinal slip, as the head does not keep up with imposed head and trunk rotation or lateral or vertical linear displacement. Aberrant afferent input could also result from altered proprioceptive input from the very effector organs of the VCR, the neck muscles. Wrisley et al<sup>12</sup> noted that hypertonicity in the sternocleidomastoid and upper trapezius muscles may cause cervicogenic dizziness. They also noted that the neck mus-

cles might become involved in a cyclic pattern where increased dizziness leads to increased muscle tone, which in turn might increase complaints of dizziness<sup>12</sup>. Normalization of function of the neck muscles after dysfunction due to, e.g., tensile strain post-whiplash injury or reflex activation due to dysfunction in neighboring joints, may thus decrease complaints of dizziness due to normalization of afferent and efferent mechanisms. The connection by way of the VCR between the otolith organs and the ipsilateral sternocleidomastoid muscle also explains the lateral head tilt seen in patients with otolith dysfunction<sup>8</sup>.

### **Vascularization**

The vascular supply to the vestibular system serves a vital role in its proper functioning. Compromise of the blood supply to the brain may cause dizziness<sup>13</sup>. The vertebrobasilar system provides the arterial supply to both the peripheral and central vestibular system. The vertebral artery branches off the subclavian artery and courses superiorly through the transverse foramina of C6 to C1. It then pierces the dura mater to enter the subarachnoid space. Before uniting to form the basilar artery, the vertebral arteries give off the posterior inferior cerebellar artery, which provides the vascular supply to the cerebellum and the inferior vestibular nuclear complex. The basilar artery provides the vascular supply to the central vestibular structures located in the pons and its branch, the anterior inferior cerebellar artery, supplies the lower pons, the ventrolateral cerebellum, and by way of the labyrinthine or internal auditory artery, the peripheral vestibular system<sup>1</sup>. Through the circle of Willis, the vertebrobasilar system anastomoses with the internal carotid arteries and is a source of pancerebral perfusion.

### **Clinical implications based on vascularization**

Vascular compromise can take the form of decreased blood volume and flow, but also of decreased oxygenation or glucose content<sup>7</sup>. History taking of the patient complaining

of dizziness should include questions to identify pathologies that can affect pancerebral as well as brainstem perfusion; this includes screening for cardiovascular and pulmonary disorders and diabetes<sup>7</sup>. Examination may need to include blood pressure and heart rate measurements; cardiac, pulmonary and carotid auscultation; vertebrobasilar insufficiency tests; and hyperventilation and Valsalva tests<sup>8</sup>.

Vascular compromise resulting in dizziness and other associated symptoms may be expected to have a relatively long latency period: sufficient compromise needs to occur to produce symptoms. This is in contrast to dizziness as a result of proprioceptive dysfunction: cervicogenic dizziness has an immediate onset upon assuming a position that depolarizes the proprioceptors involved. Dizziness due to BPPV has a latency of a few seconds upon assuming a provocative position as a result of inertial effects of the fluid flow in the semicircular canals<sup>7</sup>. One could call the dizziness as a result of vascular compromise positional dizziness to distinguish it from the positioning dizziness produced by cervicogenic and BPPV-related dizziness<sup>7</sup>. Vascular dizziness and associated signs and symptoms will also increase in intensity until the vascular compromise is resolved. In contrast, the other two types of dizziness will decrease and accommodate upon maintaining the provocative position<sup>7</sup>. This will help in interpretation of tests with a similar head and neck position, i.e., the cervical extension-rotation test, the Hallpike-Dix maneuver, and the neck torsion test.

### **Physiology**

As mentioned above, balance involves multi-sensory and cognitive integration to produce a coordinated and appropriate motor output. It requires proper function of the vestibular, auditory, visual, tactile, proprioceptive, and cognitive systems on the input side; proper function of the vestibular nuclear complex and the cerebellum in the central processing unit; and proper function of the extra-ocular and skeletal (including cervical) muscles and surrounding musculoskeletal



tissues on the output side. We will discuss vestibular and relevant visual system physiology.

The vestibular system consists of a peripheral sensory apparatus, which through its central processing unit is coupled to a mechanism for motor output<sup>1,14</sup>. The vestibular system has three main functions<sup>2,3</sup>:

1. Sensing and perceiving motion
2. Gaze stabilization
3. Postural control

Sensing and perceiving motion relies on the hair cell function in the sensory organs. The semicircular canals provide sensory information regarding head velocity and angular head movements<sup>1,3</sup>. As a result of their bilateral perpendicular orientation, the six individual semicircular canals pair up to form three coplanar pairs: one pair consists of both horizontal canals, one of the left anterior and right posterior canals, and a final one of the right anterior and left posterior canals<sup>1</sup>. This allows for a “push-pull” mechanism of bilateral input: angular head movement will result in increased firing rates through one vestibular nerve with simultaneous decreased firing rates through the contralateral nerve<sup>1</sup>. Flow of the endolymphatic fluid in response to head movement causes a deflection of the cupula bending the hair cells in the direction opposite to that of the endolymphatic flow<sup>1,3</sup>. The direction of bending of the longest hair cell determines whether the firing rate of the vestibular nerve increases or decreases<sup>1</sup>. For example, with right rotation of the head in the horizontal plane, the endolymphatic fluid in the right horizontal semicircular canal will flow to the left, deflecting the hair cells to the right. This depolarizes the vestibular neurons thus increasing the firing rate of the right vestibular nerve. Simultaneously, the cupula of the left semicircular canal is also deflected to the right with the endolymphatic fluid flowing to the left. This hyperpolarizes the neurons thus decreasing the firing rate of the left vestibular nerve. The opposite effect occurs with left rotation. A similar mechanism is active for the other orthogonal angular movements. In the horizontal semicircular canal flow of the endolymph

towards the utricle (utricopetal flow) causes increased neuronal activity and flow away from the utricle (utricofugal flow) results in decreased neuronal activity<sup>2</sup>. This situation is reversed in the posterior and anterior semicircular canals where utricopetal flow causes inhibition and utricofugal flow results in excitation<sup>2</sup>. The semicircular canals function as acceleration sensors for head motion frequencies of 0.1–5 Hz<sup>2</sup>.

The otoliths provide sensory information on linear motion and acceleration. Linear translations will cause the otoconia to produce a shearing force over the maculae, which changes the discharge frequency of the vestibular nerve<sup>1</sup>. The utricle is sensitive to horizontal linear accelerations and the saccule is sensitive to vertical linear accelerations. Direction of sensitivity is attributable to the orientation of the sensors, horizontal for the utricle and vertical for the saccule<sup>1</sup>. The otoliths also provide information on head tilt because the incorporation of the otoconia in the otolithic membranes makes them sensitive to gravity<sup>1</sup>. A “push-pull” mechanism also exists for the otolithic organs<sup>1</sup>.

The VOR is responsible for gaze stabilization during head movement: a person is able to maintain a stable and clear view of an object when the head moves because compensatory eye movements occur due to the action of the VOR in the opposite direction<sup>1,3</sup>. The velocity of the eye movement is equal, but opposite to that of the head movement<sup>3</sup>. The sensory information for the VOR is provided by the semicircular canals<sup>1</sup>. The close spatial relationship of the plane of the extra-ocular muscles facilitates this reflex<sup>1</sup>. In fact, neuronal activity in the paired semicircular canals results in a compensatory eye movement in the plane of those canals that were stimulated<sup>2</sup>. The VOR is most effective in maintaining gaze stabilization for head movement speeds between 1–5 Hz<sup>2</sup>.

Additional mechanisms exist in addition to the VOR for maintaining clear visual images. The smooth pursuit system allows for tracking of a visual target with a smooth continu-

ous eye movement. This system is increasingly effective if the frequency of head movement stays below 0.1 Hz but functions up to 1 Hz. The cerebellar flocculus, nodulus, and posterior vermis and at times also the rest of the cerebellum, the brain stem, and some cortical areas are involved in the smooth pursuit system<sup>2</sup>. The saccadic system of eye movement produces single rapid eye movements that reposition a visual target onto the fovea. Cortical areas, the paramedian pontine reticular formation, and the vestibulocerebellum are involved in this system<sup>2</sup>. The optokinetic response integrates smooth pursuit and saccadic systems for tracking repeated movements across the field of view, when a person is moving in a stationary visual field, or in combinations of both situations. It shares the same brain stem and cerebellar pathways as the smooth pursuit and saccadic systems<sup>2</sup>. The cervico-ocular reflex (COR) originates in the proprioceptors of the upper cervical spine (C1-C3)<sup>1,15</sup>. This reflex has a function similar to that of the VOR albeit in a much lower frequency range of head velocities: the COR functions to stabilize gaze at frequencies of head movement below 0.5 Hz<sup>1,16</sup>. All systems integrate with the VOR for accurate visual perception. Difficulty with or inability to maintain gaze stabilization may cause symptoms of dizziness<sup>1,3</sup>. This dizziness is magnified when the head moves, which is why patients with vestibular disorders tend to minimize head movement<sup>17</sup>.

The purpose of the VSR is to stabilize the body during head movement<sup>1</sup>. Head movement to one side results in ipsilateral extensor activity and contralateral limb flexor activity<sup>1</sup>. With a vestibular lesion, the VSR will be compromised and the patient has difficulty stabilizing the body in response to head movement<sup>1</sup>. This creates a sense of dysequilibrium or difficulty maintaining upright posture against gravity. The VSR is supplemented by the cervicospinal reflex (CSR), a somatosensory reflex also originating in the upper cervical spine<sup>1,15</sup>. The CSR contributes to coordinated limb responses by producing extensor and flexor activity opposite to that produced by the VSR<sup>1</sup>.

These reflexes may, of course, also be impaired by interruption of the reflex circuit anywhere along its course, implicating processes affecting the spinal cord and spinal and peripheral nerves as possible etiological factors in dizziness.

### Clinical implications based on physiology

Vestibulo-ocular tests include the dynamic visual acuity; doll's head; head-shaking nystagmus; and head thrust tests<sup>8</sup>. These test the gaze stabilization mechanisms described above. Tests of smooth pursuit and saccadic eye movements may implicate or clear central structures in case of a positive response on the vestibulo-ocular tests<sup>8</sup>. Further cerebellar tests<sup>8</sup> may be positive when smooth pursuit and saccadic eye movements are impaired. The neck torsion test may implicate the upper cervical spine and a resultant aberrant afferent input through the COR for complaints of dizziness. Disturbance of the cervical reflexes (COR and CSR), due to cervical spine injury, dysfunction or faulty posture, is hypothesized to contribute to dizziness originating from the upper cervical spine, otherwise known as cervicogenic dizziness<sup>18-20</sup>. We discussed above the cyclic pattern of cervical hypertonicity and dizziness through altered afferent and efferent activity<sup>12</sup>. Cervicogenic dizziness may be secondary to an attempt to minimize head movement in patients with a decreased gaze stabilization mechanism<sup>17</sup> or may occur in patients with a lateral head tilt due to otolith dysfunction<sup>1</sup>: adaptive shortening or excessive muscle tone in the upper cervical region may result in aberrant proprioceptive input resulting a mixed vestibular and cervicogenic origin for complaints of vertigo.

The close anatomical relationship between the plane of the semicircular canals and the eye movements produced by the extra-ocular muscles allows for differential diagnosis of central versus peripheral vestibular dysfunction on positional maneuvers and other tests involving positioning of the head and neck. Horizontal nystagmus can result from horizontal semi-

circular canal dysfunction, but a purely vertical nystagmus would have to be the result from a combined contralateral anterior and posterior canal dysfunction making it highly unlikely that such a nystagmus is the result of solely peripheral vestibular lesions and, therefore, leading the clinician to suspect central involvement<sup>2</sup>. Isolated anterior and posterior semicircular canal dysfunction tends to result in a torsional nystagmus, although a vertical downbeating nystagmus has been reported for anterior canal dysfunction<sup>21</sup>. Examination of patients complaining of dizziness needs to include positional maneuvers including the Hallpike-Dix, straight head hanging, roll, and walk-rotate-walk tests with careful attention to the direction of a possible nystagmus<sup>8</sup>. Observation of the direction and latency of onset of nystagmus and other associated symptoms will also help in the differential diagnosis of peripheral versus central involvement in other tests involving head and neck movement, such as the neck torsion test and the cervical extension-rotation test<sup>7,8</sup>.

Clinical examination of patients complaining of dizziness may also include so-called vestibulospinal tests, e.g., variations of the Romberg, single leg balance, and Fukuda step tests<sup>8</sup>. Whereas the vestibulo-ocular tests allow for a somewhat accurate level of differential diagnosis<sup>8</sup>, it should be clear from the description of the multitude and complexity of neurological and musculoskeletal systems involved in balance control during these tests that the vestibulospinal tests may indicate vestibular, visual, and proprioceptive components to complaints of dizziness but that they are neither sensitive nor specific.

This "push-pull" mechanism of the paired semicircular canals and the otolith organs described above allows for sensory redundancy. In the case of unilateral vestibular hypofunction the central vestibular system still receives information from the contralateral semicircular canal or otolith organ<sup>1</sup>. This allows for a therapeutic effect by way of substitution and habituation as a result of specific therapeutic exercise intervention.

### Conclusion

Under normal functioning conditions, the vestibular nuclei and the cerebellum process and integrate incoming sensory information from the vestibular, visual, and somatosensory systems important for postural control<sup>1</sup>. Auditory input and cognitive knowledge of impending movement also play a role in postural control<sup>1</sup>. The visual system provides an external reference point for the body via targets and the visual surround. Information regarding the position and motion of joints, length and tension of muscles, and the condition of the support surface is provided by the somatosensory system. The central vestibular system relies on each of these symptoms to determine the body's position in space and to detect if movement has occurred<sup>14</sup>. However, aberrant sensory input from one or more of the peripheral sensory systems can confuse the central system. This confusion is caused by a sensory mismatch among the vestibular, visual, and somatosensory systems and results in dizziness<sup>18</sup>. This concept is important to understand, because it explains why the vestibular system is not the only system that can cause a patient to complain of dizziness<sup>18</sup>.

Based on a discussion of the anatomy, vascularization, and physiology of the vestibular system this article has clarified the need for a multi-system evaluation of patients complaining of dizziness while at the same time providing information relevant to differential diagnosis and possible intervention. A comprehensive history and examination within the scope of orthopaedic physical therapy practice is discussed in a separate article<sup>8</sup>.

### References

1. Hain T., Ramaswamy T., Hillman M.: Anatomy and physiology of the normal vestibular system. In: Herdman S.J., ed., *Vestibular Rehabilitation*. 2<sup>nd</sup> ed. Philadelphia, PA: FA Davis Company, 2000
2. Shepard N.T., Telian S.A.: Balance system function. *Am. J. Audiol.*, 1992; 1(3): 45-51
3. Schubert M., Herdman S.J.: *Vestibular rehabilitation*. W. Schmitz T., ed. *Physical Rehabilitation: Assessment and Treatment*. 4<sup>th</sup> ed. Philadelphia, PA: FA Davis Company, 1994
4. Gdowski G.T., McCrea R.A.: Integration of vestibular and head movement signals in the vestibular nuclei during whole-body rotation. *J. Neurophysiol.*, 1999; 81: 436-449

5. Watson SRD., Colebatch J.G.: Vestibulocollic reflexes evoked by short-duration galvanic stimulation in man. *J. Physiol.*, 1998; 513: 587–597
6. Furman J.M., Whitney S.L.: Central causes of dizziness. *Phys. Ther.*, 2000; 80: 179–187
7. Huijbregts P., Vidal P.: Dizziness in orthopaedic physical therapy practice: Classification and pathophysiology. *J. Manual Manipulative Ther.*, 2004; 12: 196–211
8. Vidal P., Huijbregts P.: Dizziness in orthopaedic physical therapy practice: History and physical examination. Submitted for publication *J. Manual Manipulative Ther.*
9. Grimm R.J.: Inner ear injuries in whiplash. *Journal of Whiplash & Related Disorders*, 2002; 1: 65–75
10. Horn L.B.: Differentiating between vestibular and nonvestibular balance disorders. *Neurology Report*, 1997; 21(1): 23–27
11. Alexander N.B.: Postural control in older adults. *J. Am. Geriatr. Soc.*, 1994; 42: 93–108
12. Wrisley D.M., Sparto P.J., Whitney S.L., Furman J.M.: Cervicogenic dizziness: A review of diagnosis and treatment. *J. Orthop. Sports Phys. Ther.*, 2000; 30: 755–766
13. Drachman D.A., Hart C.W.: An approach to the dizzy patient. *Neurology*, 1972; 22: 323–334
14. Horak F.B., Shupert C.: Role of the vestibular system in postural control. In: Herdman S.J., ed. *Vestibular Rehabilitation*. 2<sup>nd</sup> ed. Philadelphia, PA: FA Davis Company, 2000
15. Brown J.: Cervical contributions to balance: Cervical vertigo. In: Graf W., ed. *The Head Neck Sensory Motor System*. New York, NY: Oxford University Press, 1992
16. Bronstein A.M.: Vestibular reflexes and positional maneuvers. *J. Neurol. Neurosurg. Psychiatry*, 2003; 74: 289–293
17. Herdman S.J., Whitney S.L.: Treatment of vestibular hypofunction. In: Herdman S.J., ed. *Vestibular Rehabilitation*. 2<sup>nd</sup> ed. Philadelphia, PA: FA Davis Company, 2000
18. Norre M.E.: Neurophysiology of vertigo with special reference to cervical vertigo: A review. *Acta Belg. Med. Phys.*, 1986; 9: 183–194
19. Paris S.V.: Cervical symptoms of forward head posture. *Top Geriatr. Rehabil.*, 1990; 5(4): 11–19
20. Souza T.A.: *Differential Diagnosis for the Chiropractor: Protocols and Algorithms*. Gaithersburg, MD: Aspen Publishers, 1997
21. Bertholon P., Bronstein A.M., Davies R.A., Rudge P., Thilo K.V.: Positional downbeating nystagmus in 50 patients: Cerebellar disorders and possible anterior semicircular canal canalithiasis. *J. Neurol. Neurosurg. Psychiatry*, 2002; 72: 366–372

**Address for correspondence**

Dr. Peter A. Huijbregts, PT,  
 Shelbourne Physiotherapy,  
 100B–3200 Shelbourne Street, Victoria,  
 BC V8P 5G8 Canada  
 e-mail: shelbournephysio@telus.net

*Translated from Polish  
 to English language:  
 Marcin Tutaj, MD*